



PATIENT

Cap Johnson

PRESENTING CLINICAL SIGNS

History: Severe systolic heart murmur. Cryptorchid. Assess prior to breeding.

SPECIES

Canine

ECHOCARDIOGRAM FINDINGS

2D, m-mode, color flow and doppler imaging is available. The mitral valve appears normal with no prolapse into the left atrial lumen. No mitral regurgitation. No left atrial enlargement. Normal LV diameter with adequate myocardial function. A relatively large ventricular septal defect is identified. VSD flow appears primarily left to right; however, max velocity is unable to be measured. The tricuspid valve appears normal with no tricuspid regurgitation. The right atrium is mildly enlarged and the right ventricular is moderate to severely enlarged with significant hypertrophy consistent with pressure overload. The pulmonic valve is difficult to visualize extensively; however, a valvular stenosis is suspected. Pressure gradient through the region is severely elevated. No significant PI. Post stenotic dilation is seen. The aortic valve appears largely normal although difficult to visualize extensively. No significant AI. No pericardial or pleural effusion noted. No obvious cardiac masses.

BREED

Border Collie

SEX

Male

AGE

11 weeks

CARDIAC CHART

WEIGHT

11lbs

CANINE CARDIAC PARAMETERS	MR VMAX (m/s)	TR VMAX (m/s)	LA/AO (Boon method)	LA/AO (Heart Base; Swe)	FS (%)	EF (%)	EPSS (cm)
NORMAL PARAMETER	4.5-5.5	<2.7	1.3	<1.6	28-40	40-100	<0.6
PATIENT	NA	NA	1.4	1.1	54	87	NM
CANINE CARDIAC PARAMETERS	HR (BPM)	AV VMAX (m/s)	PV MAX (m/s)	BODY WEIGHT (kg)	LA 2D short axis Base view (cm)	LVIDd Avg; 2D and m-mode short axis (cm)	LVIDs Avg; 2D and m-mode short axis (cm)
NORMAL PARAMETER	50-100	0.7-1.7	0.7-1.6	BELOW	BELOW	BELOW	BELOW
PATIENT	140	1.7	5.0	5.0	wnl	2.1	1.0
*Normal chamber parameters expressed as a mean value (SD)				3	1.27 (5.3)	2.46 (2.46)	1.36 (5.5)
BODY WEIGHT DEPENDENT PARAMETERS				5	1.40 (4.5)	2.74 (5.2)	1.60 (4.7)
<i>*Note: All measurements based upon multi-modal images and methods. An average value is reported.</i>				10	1.50 (3.8)	3.27 (3.5)	2.06 (3.1)
				15	1.83 (2.0)	3.71 (2.4)	2.43 (2.1)
				20	2.02 (1.9)	4.14 (2.2)	2.80 (2.0)
				25	2.18 (2.4)	4.48 (2.9)	3.10 (2.5)
				30	2.33 (3.3)	4.83 (3.9)	3.39 (3.4)
				35	2.48 (4.3)	5.17 (5.0)	3.69 (4.5)
				40	2.62 (5.2)	5.48 (6.1)	3.96 (5.4)
				50	2.88 (7.1)	6.07 (8.3)	4.46 (7.4)

INTERPRETED BY

Maggie Machen Lamy, DVM, DACVIM (Cardiology)

IMAGING PERFORMED BY

Lindsey Daniel, DVM

HOSPITAL NAME

Moore's Mill Animal Hospital

REFERRING VET

Dr. Puckett

INTERPRETATION OF THE FINDINGS & FURTHER RECOMMENDATIONS

Complex congenital heart disease is present, with both a VSD and significant pulmonic stenosis. This is likely a form of Tetralogy of Fallot (TOF) although an over-riding aorta is not clearly seen. The PS is presumptively primarily valvular; however, a dynamic sub or supra-valvular component is not entirely ruled out. The VSD is mostly left to right on color flow, although a relatively low max velocity is suspected. No additional congenital defects are observed; however, it is important to note that small changes are easily missed particularly given the abnormality of this cardiac exam.

INVOICE

21843

DATE

11/2/21



PATIENT

Cap Johnson

Given the complexity of the findings, consider referral to an attending Cardiologist in this case for advanced echocardiography and conformation of the diagnosis. Surgical options can be discussed although long-term benefit is questionable in this case. If referral is declined, recommend institute medical management with Atenolol once the puppy is 6 months old. No additional medications are indicated at this time.

SPECIES

Canine

Assessment of progression in the future will help predict long term prognosis, which is guarded to poor going forward. There is a chance that the combination of right-sided issues may stable for some time; however, the patient will always be at risk for progression to right-sided CHF, symptoms of hypoxia, polycythemia, etc. Additionally, the severity of the aortic leak is concerning and may lead to LV volume overload going forward. Arrhythmias/collapse and/or sudden death is also a possibility. Hypoxic heart disease will often present as marked exercise intolerance, cyanosis and syncope at home.

BREED

Border Collie

SEX

Male

Breeding this animal is certainly not advised due to the genetic link of congenital disease.

AGE

11 weeks

Omega fatty acid supplementation and mild salt restriction may be of some long-term benefit. Lifelong activity restriction is advised. Elective anesthesia is not advised. If necessary, referral to a facility with an Anesthesiologist should be considered.

WEIGHT

11lbs

Monitor for development of a cough, labored breathing, abdominal distention, exercise intolerance or collapse episodes.

PLAN

Highly recommend referral. If declined and once the puppy is 6 months old, Institute low dose Atenolol 25mg tabs; ¼ tab PO q24h. Up-titrate to effect; target heart rate is <140bpm in hospital. A baseline BP is recommended. A baseline PCV is also recommended.

Recommend conservative monitoring with a recheck echocardiogram in 6 months, sooner if any development of clinical signs.

INTERPRETED BY

Maggie Machen Lamy,
DVM, DACVIM
(Cardiology)

IMAGING PERFORMED BY

Lindsey Daniel,
DVM

HOSPITAL NAME

Moore's Mill Animal
Hospital

REFERRING VET

Dr. Puckett

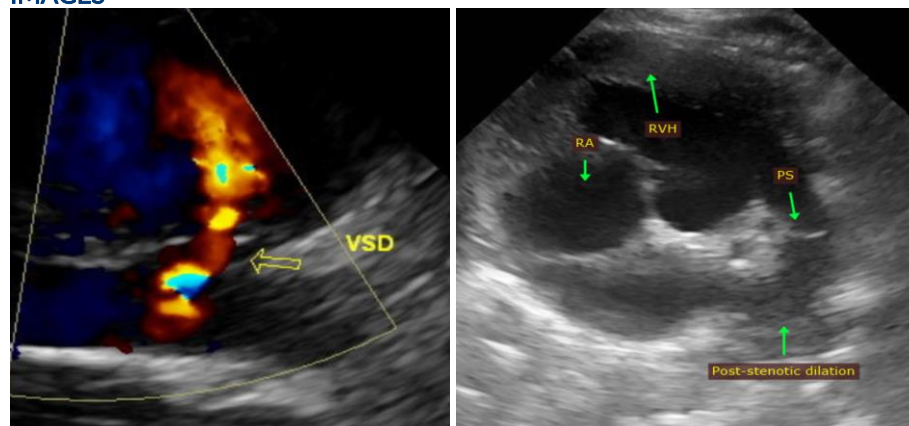
INVOICE

21843

DATE

11/2/21

IMAGES





PATIENT

Cap Johnson

The information and recommendations provided are based on the images presented by the referring veterinarian. No evaluation can be communicated regarding pathology that was not visible in the image/video clips provided.

SPECIES

Canine

Thank you for this referral. This report was generated using transcription software, and minor dictation errors may be present. If the clinical or image interpretation does not parallel your findings or if I can be of any further assistance, please contact me.

BREED

Border Collie

Maggie Machen Lamy, DVM
Diplomate of the American College of Veterinary Internal Medicine (Cardiology)
info@sonopath.com

SEX

Male

AGE

11 weeks

WEIGHT

11lbs

INTERPRETED BY

Maggie Machen Lamy,
DVM, DACVIM
(Cardiology)

**IMAGING
PERFORMED BY**

Lindsey Daniel,
DVM

HOSPITAL NAME

Moore's Mill Animal
Hospital

REFERRING VET

Dr. Puckett

INVOICE

21843

DATE

11/2/21